




Universidad Galileo Guatemala  
Instituto Panamericano Contra la Ceguera  
Facultad de Ciencias de la Salud.  
Maestría en Oftalmología Integral



*Galileo*  
UNIVERSIDAD  
La Revolución en la Educación

# AIR TAMPONADE WITH 24 HRS FACE DOWN POSITION IN INVERTED ILM FLAP FOR LARGE MACULAR HOLES CASE SERIES

Autor: González Castor Diana Catalina  
Revisor: Gutiérrez Paz Mario Augusto  
Asesor: Gutiérrez Paz Mario Augusto  
15 de diciembre de 2021

# AIR TAMPONADE WITH 24 HRS FACE DOWN POSITION IN INVERTED ILM FLAP FOR LARGE MACULAR HOLES CASE SERIES

González Castor, Diana Catalina, Gutiérrez Paz, Mario Augusto

## Abstract

**Intro.** To evaluate the ILM inverted flap surgical technique with fluid-air exchange with 24hrs FDP in Large MH

**Methods.** Prospective case series in Instituto Panamericano Contra la Ceguera, Guatemala

**Results.** MH in all of our patients closed with good structural and visual outcomes with a single technique at 6<sup>th</sup> month follow up.

**Conclusion.** ILM inverted flap technique with fluid-air exchange with 24 hrs FDP seems to be a safe and effective surgery in large MH cases.

**Keywords:** Internal limiting membrane, inverted flap, large macular hole, face down position, fluid-air exchange

## Introduction

Macular holes (MH) formation is given by the centrifugal tangential traction of an anomalous posterior vitreous detachment. They mostly occur in the sixth to seventh decade of life with female preponderance<sup>1</sup>, in general population varies from 0.2 to 3.3 per 1,000.<sup>2</sup> Large macular holes have been described as those larger than 400 µm located in the fovea involving all retinal layers. They account up to 44% of risk surgical failure with conventional removal or peeling of the internal limiting membrane (ILM).<sup>3</sup> Michalewska et al. have proposed a new strategy to increase the surgical success in large MH cases, using an inverted flap technique to aim the flattening and reposition of the MH edges which increases the rate up to 98% of surgical success in large MH.<sup>3,4</sup> There's also been described for large MH approach the use of autologous retinal transplantation, transforming bovine growth factor B<sub>2</sub>, autologous platelet concentrate or human amniotic membrane.<sup>5,6,7,8,9,10</sup>

The aim of this case series is to report for the first time in the literature the success on a single surgery closure rate visual and structural changes in ILM flap technique with air tamponade and 24hrs face down position for large MH.

## **Materials and Methods**

This is a prospective case series of patients diagnosed with idiopathic large macular holes (minimum diameter >400 µm), regardless of their BCVA and lens status. Patients with any other retinal pathology were excluded, glaucoma, diabetic retinopathy, AMD, myopia >3D or AL > 26 mm. The SD-OCT diagnosis and measures were taken with Optovue (Fremont, CA), taking into consideration macular hole index (MHI)<sup>11</sup>, the ellipsoid zone (EZ) and external limiting membrane (ELM) endline measures at day 0, 3<sup>rd</sup> and 6<sup>th</sup> month postoperative as predictors for functional outcomes. The same experimented surgeon operated on these eyes under sedation and local anesthesia with the same technique.

All patients underwent an extensive eye examination including best-corrected visual acuity (BCVA) testing, dilated fundus examination with slit-lamp biomicroscopy and color fundus photography. Data collected included demographics, BCVA and OCT measures through their 6 months visits and surgical details and complications, if any. The BCVA was assessed using Snellen's chart and then converted to LogMAR for analysis.

## **Statistical Analysis**

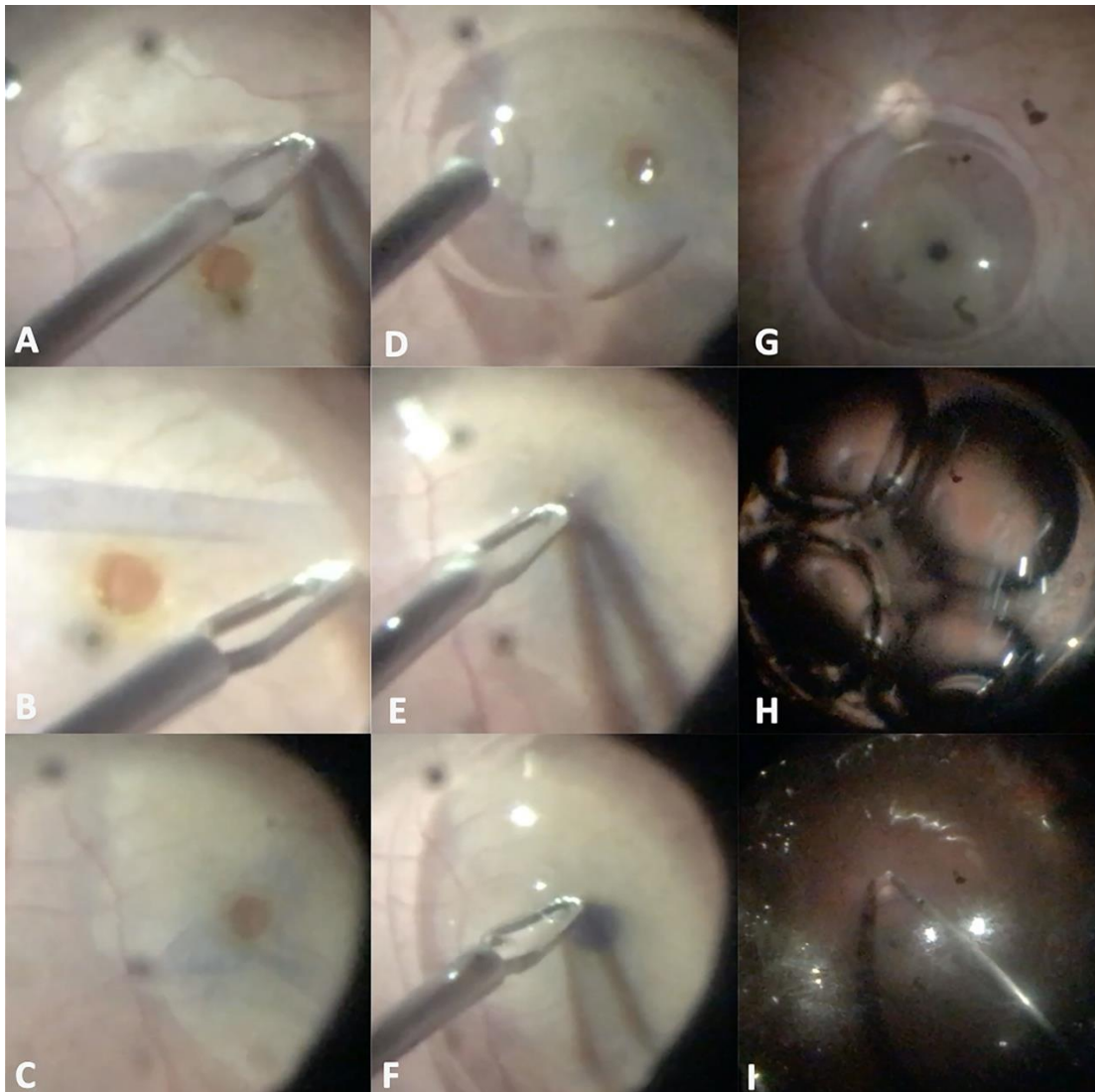
Statistical analysis was undertaken using IBM SPSS for Windows, V.10 (Lenovo, IntelCore i3-1005G1). Variables corresponded to BCVA, hole height, base and minimum diameter, ELM and EZ measures. The measures of interest in postoperative follow up were BCVA, the EZ status and defect measures, ELM status and defect measures in the current analysis, and MHI (greater than 0.5 carries a better prognosis).<sup>10</sup> Binary logistic regression analyses were derived, using both structural and visual success as the outcome measures.

Comparisons between the measures of interest were made using the T-test.  $P \leq 0.05$  was considered statistically significant.

## **Surgical Technique**

The surgery was performed with a 23G pars plana vitrectomy (PPV), and in phakic cases independent of lens status combined surgery of PPV with phacoemulsification and IOL implantation. ILM stained by brilliant blue G 250 (BBG). Peel off the ILM in a circular manner (2-disc diameters) around de hole without touching the MH borders. If epiretinal membrane was observed, it was previously removed. Next, 1cc of perfluorocarbon (PFC)

was placed in order to cover the hole and the ILM flap was done, introducing the free borders of the ILM into the hole and covering it using the grasp forceps. Finally, fluid-air exchange was performed, and the PFC is taken off with the silicon cannula over the optic nerve disc, avoiding manipulation of the silicon cannula near the ILM flap preventing inadvertent aspiration of the flap. Patients were advised to maintain face down position for only 24 hours.



**Figure 1.**

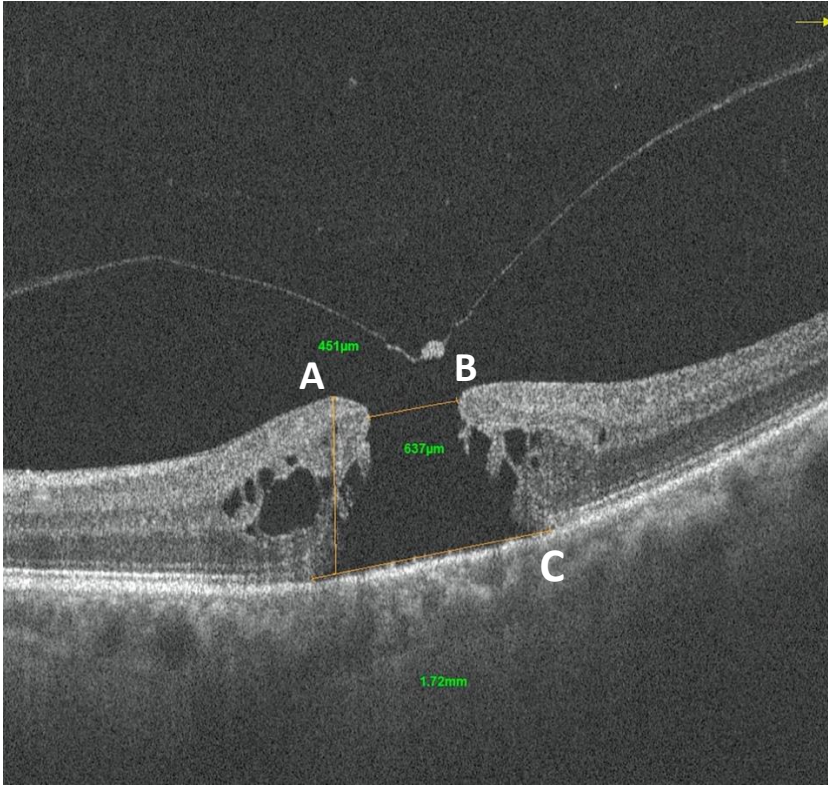
**A**, ILM peeling with Grieshaber DSM ILM forceps (Alcon laboratories, Inc) **B**, 2-disc diameters (DD) of ILM peeling in a circular manner. **C**, Creating the ILM free flap. **D**, PFC bubble above the MH and ILM flap. **E**, **F**, placing ILM free borders into the hole with forceps. **G**, PFC's bubble view with the MH closed by the ILM flap **H**, **I**, Fluid-air exchange with PFC aspiration with a silicone cannula over the optic nerve, avoiding macular hole and ILM flap.

## Results

In this prospective case series, 5 patients were enrolled (5 eyes in total) with criteria of idiopathic large macular holes (minimum diameter >400  $\mu\text{m}$ ). Four of them female and one male, with a mean age of  $63.2 \pm 2.58$  years (60-67 years). From each OCT study, it was manually assessed with the caliper software tool, we also took into consideration the minimum diameter between edges (mean  $589.4 \pm 138.27$   $\mu\text{m}$ ), the maximum diameter at base in the retinal pigment epithelium (mean  $1354 \pm 228.86$   $\mu\text{m}$ ) and the macular hole height (mean  $419.4 \pm 26.67$   $\mu\text{m}$ ) which goes from retinal pigment epithelium to the vitreoretinal interface (**Table 1**). Afterwards, we calculated the macular hole index (MHI) ratio of the macular hole height to its base diameter with a mean of  $0.31 \pm 0.04$   $\mu\text{m}$ . **Figure 2**

**Table 1.** Baseline Characteristics of the patients

	CASE 1	CASE 2	CASE 3	CASE 4	CASE 5	Mean $\pm$ SD
<b>Gender</b>	Female	Female	Female	Female	Male	
<b>Basal BCVA (LogMAR)</b>	1.3	1.6	0.8	0.7	1.6	$1.2 \pm 0.43$
<b>Age y</b>	62	67	63	60	64	$63.2 \pm 2.58$
<b>MH minimum DM (<math>\mu\text{m}</math>)</b>	614	637	782	484	430	$589.4 \pm 138.27$
<b>MH base DM (<math>\mu\text{m}</math>)</b>	1100	1720	1250	1360	1340	$1354 \pm 228.86$
<b>Height (<math>\mu\text{m}</math>)</b>	400	451	426	435	385	$419.4 \pm 26.67$
<b>MHI (<math>\mu\text{m}</math>)</b>	0.36	0.26	0.34	0.32	0.28	$0.31 \pm 0.04$
BCVA= Best corrected visual acuity, MH= macular hole, y= years, DM= diameter, MHI= macular hole index, $\mu\text{m}$ = micrometers, $\pm$ SD= standard deviation						



**Figure 2**

Macular hole index (MHI= Height / Maximum basal diameter)

Case 2 measures examples.

**A**, Height (451  $\mu\text{m}$ ) **B**, Minimum diameter (637  $\mu\text{m}$ ). **C**, Basal diameter (1720  $\mu\text{m}$ )

### Functional Results

After surgery, compared to the initial BCVA, patients experienced a mean improvement in visual acuity of  $0.12 \pm 0.08$  LogMAR 1 week after surgery ( $p= 0.15$ ),  $0.2 \pm 0.14$  LogMAR at 1<sup>st</sup> month ( $p= 0.04$ ),  $0.24 \pm 0.16$  LogMAR at 3<sup>rd</sup> month ( $p= 0.02$ ), and  $0.4 \pm 0.28$  LogMAR at 6<sup>th</sup> month ( $p= 0.02$ ) in the postoperative visit Comparisons between initial BCVA and final BCVA were made using the paired one-tailed T-test, statistical analysis revealed there was a statistically significant difference noted. **Table 3.**

### Structural Results

Successful MH closure was achieved in the five cases. Ellipsoid zone defects were noted in all cases at 3<sup>rd</sup> (mean  $536.6 \pm 205$   $\mu\text{m}$ ) and 6<sup>th</sup> month postoperative (mean  $476 \pm$

210.04  $\mu\text{m}$ ). Comparisons between the preoperative defect and the 6<sup>th</sup> month postoperative defect showed statistically significant difference of  $p= 0.003$ , which shows restauration of the EZ between the initial defect and the 6<sup>th</sup> month postoperative visit with a mean of  $878 \pm 620.83 \mu\text{m}$  ( $p= 0.003$ ).

ELM regeneration also was found in all of cases with a statistically significant difference comparing 3<sup>rd</sup> month (mean  $361.6 \pm 274.43 \mu\text{m}$ ) and 6<sup>th</sup> month postoperative ( $280.4 \pm 233.49 \mu\text{m}$ ,  $p= 0.01$ ), with a mean of improvement of  $1073 \pm 759.14 \mu\text{m}$  between the initial defect and the 6<sup>th</sup> month postoperative visit ( $p= 0.002$ ). **Figure 3, Table 4 and 5**

**Table 3.** BCVA LogMAR change during 6 months follow up.

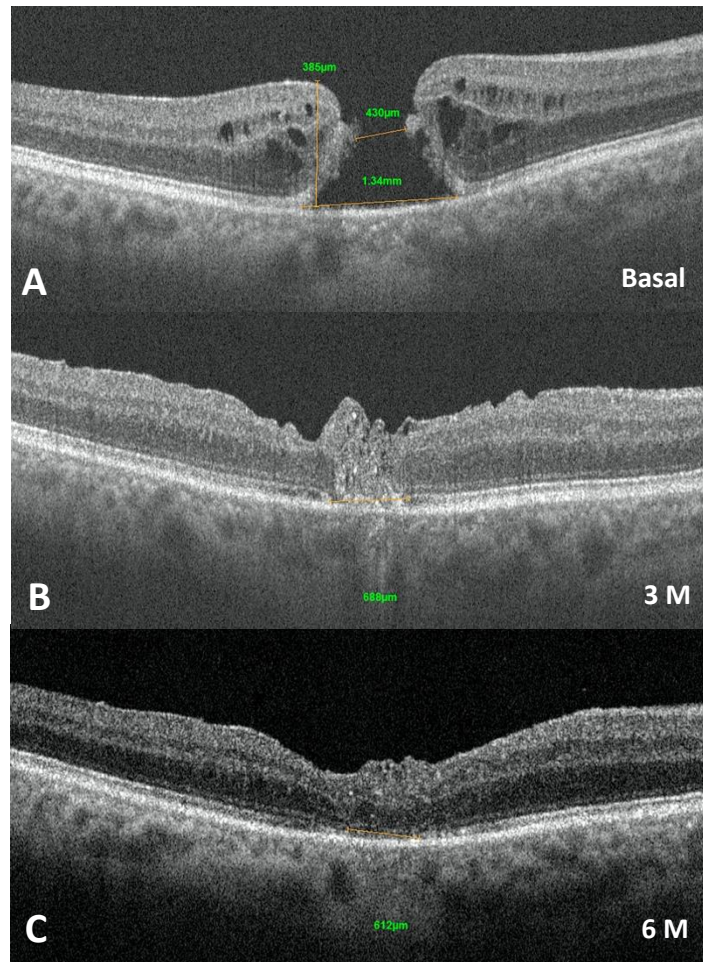
BCVA (LogMAR)	Basal	1 day	1 week	1 M	3 M	6 M
<b>CASE 1</b>	1.3	HM	0.8	0.8	0.8	0.8
<b>CASE 2</b>	1.6	HM	1.5	1.5	1.3	1.0
<b>CASE 3</b>	0.8	HM	0.8	0.8	0.8	0.8
<b>CASE 4</b>	0.7	HM	0.6	0.6	0.6	0.6
<b>CASE 5</b>	1.6	HM	1.5	1.3	1.3	0.8
<b>MEAN <math>\pm</math> SD</b>	$1.2 \pm 0.43$	HM	$1.08 \pm 0.38$	$1 \pm 0.38$	$0.96 \pm 0.32$	$0.8 \pm 0.14$
<b>P &lt;0.05</b>			0.15	0.04	0.02	0.02
HM= hand motion, M= month, BCVA= best corrected visual acuity, $\pm$ SD= standard deviation						

**Table 4.** Outer retina structural outcomes (EZ/ ELM defects measures), during 6 months follow up.

	3 M EZ ( $\mu\text{m}$ )	6 M EZ ( $\mu\text{m}$ )	3 M ELM ( $\mu\text{m}$ )	6 M ELM ( $\mu\text{m}$ )
<b>CASE 1</b>	712	662	715	602
<b>CASE 2</b>	255	247	0	0
<b>CASE 3</b>	382	247	190	120
<b>CASE 4</b>	675	612	453	380
<b>CASE 5</b>	659	612	450	300
<b>MEAN <math>\pm</math> SD</b>	$536.6 \pm 205$	$476 \pm 210.04$	$361.6 \pm 274.43$	$280.4 \pm 233.49$

EZ= ellipsoid zone, ELM= external limiting membrane, M= month,  $\mu\text{m}$ = micrometers,  $\pm\text{SD}$ = standard deviation

**Figure 3.**  
 Example of structural improvement  
 with SD-OCT measures from  
 EZ line and restoration of  
 ELM/ EZ complex  
**A**, preop. **B**, 3 M postop.  
**C**, 6 M postop.



**Table 5. Statistics**

	<i>P</i> <0.05
<b>Initial BCVA/ 6 M BCVA postop</b>	0.02
<b>Initial MH defect/ 6 M EZ defect</b>	0.003
<b>EZ defect at 3 and 6 M</b>	0.02
<b>Initial MH defect/ 6 M ELM defect</b>	0.002
<b>ELM defect at 3 and 6 M</b>	0.01

BCVA= best corrected visual acuity, EZ= ellipsoid zone, M= month, MH= macular hole, ELM= external limiting membrane



## Discussion

The inverted ILM flap technique for large MH was first described by Michalewska et al in 2009. In this method the ILM is not completely removed, but a small remnant is left on the margin of the MH to cover the defect with a 98% success rate.<sup>12</sup>

It is thought that the exact mechanism of improved surgical results is that the ILM induces glial cell proliferation, thereby producing an environment for the photoreceptors thus enhancing closure of the macular hole. This explains why we see improvement in not only the macular hole closure rate but also postoperative best corrected visual acuity. If the retina is damaged, the macrophage-like cells from the vitreous cavity infiltrate the retina, activating Müller cells (which we also find in the attached peeled of ILM itself) via TNF, therefore inducing the gliosis.<sup>13</sup> The histopathology of this tissue is not known. Another explanation might be that ILM serves as a barrier disabling the entrance of fluid into the MH and altering the outflow of the retinal pigment epithelium. Due to the peeling, it has been shown that those areas in the OCT show swelling of the inner retinal layers which is visible shortly after surgery but disappears in approximately 1 month. Swelling of the arcuate nerve fiber layer is followed by the formation of small dimples in the retinal nerve fiber layer (RNFL), referred to as dissociated optic nerve fiber layer (DONFL) appearance, which have been observed up to 6 months postoperative however, in previous studies, it does not have a significant effect on visual acuity.<sup>14</sup> ILM flap technique minimizes this unnecessary trauma compared to other techniques.

Since the first reports on surgical repair of macular holes, postoperative face-down posturing (FDP) has been part of the management regime. However, prone positioning is unpleasant and difficult for some patients with a medical condition such as sleep apnea, cervical pain, cardiovascular disease.<sup>15</sup> OCT studies have shown that flattening of retinal cysts and approximation of macular dehiscence can occur in macular holes by the first day postoperatively.<sup>16,17</sup> Isomae et al. evaluated the closure rate in patients who had undergone macular hole surgery comparing the 1 week versus 1 day positioning and observed a similar closure rate of 91.2% in the 1 week group and 90.5% in the 1 day group, showing no significant difference ( $P > 0.99$ ) nor a dehiscence of the hole.<sup>18</sup> A similar study conducted by Sano et al. showed a 93% success rate at day one ( $1.8 \pm 2.5$  days) of FDP with air tamponade showed no reopening of the MH after discontinuing the positioning, which was

significantly shorter than with SF6 ( $8.4 \pm 4.2$  days,  $P < 0.0001$ ).<sup>19</sup> Air tamponade was used more frequently in eyes with MH closure on postoperative Day 1 (72%,  $P = 0.030$ , Fisher exact probability test) than in eyes without MH closure (36%), indicating that a long-acting gas did not contribute to the MH closure in the early postoperative period.

The results of the closure rates and success are comparable to those obtained with the use of gas tamponade, however, air tamponade permits OCT to be performed shortly after surgery, (Michalewska 2010) less facedown positioning, faster absorption which lets our patients to recover vision earlier, and it also gives us an alternative for such patients who wish to travel by plane soon or those who may experience shoulder and neck discomfort.<sup>19,20</sup>

Nevertheless, we always have to keep in mind that long-acting gas works as an alternative for patients who can't maintain the posture and consideration to the elderly with comorbidities.<sup>21,22</sup> Every case must be individualized. The difference between our report and Michalewska's et al. is the positioning time, which the author told the patients to spend 3 to 4 days in the FDP.<sup>3</sup> Despite the good results they obtained, in our case series which no differs with the literature, we got similar results with a closure rate of 100% using air tamponade with only 24 hour FDP.

There's been an association of possible complications during ILM flap technique with the damage of the optic nerve fiber layer, Muller cells, photoreceptors, or iatrogenic retinal holes during surgery. This is why some authors like Michalewska et al tried to reduce these complications with the hemicircular ILM peeling temporal to the fovea but only obtained a rate of successful hole closure of only 87.5%.<sup>12,23</sup> The orientation of the inverting flap could influence surgical outcomes, in which spontaneous stripping of the inverted ILM flap during fluid-air exchange has been reported in 14% of cases.<sup>21</sup> Casini et al used the fluid-air exchange in the modified inverted ILM flap technique with a 97.5% success rate in MH closure which results in better structural and visual outcomes.<sup>24</sup>

The modified inverted ILM flap technique is a surgical maneuver primarily designed for the treatment of large MH where the remnant of the peeled ILM acts as a hinge over the MH. As mentioned previously, this remnant is then inverted on its point of attachment in such a fashion that the part primarily oriented to the vitreous cavity is made to face toward the retinal pigment epithelium, whereas the part initially touching retinal layers is oriented to the vitreous cavity.<sup>25</sup> If inadvertent stripping of the inverted ILM flap occurs, or ILM flap loss during surgery, ILM may be transplanted from a different location in the retina, allowing closure and improvement of BCVA postoperatively in cases of primary failure.<sup>26,27</sup>

Michalewska et. Al reported that the average visual acuity was 1.01 LogMAR 1 week after inverted ILM flap technique surgery; the average improved to 0.66 LogMAR at the 3<sup>rd</sup> month and 6<sup>th</sup> month postoperative visits, and then to 0.4 LogMAR at 12 months<sup>28</sup> in which our results correlate showing as well BCVA improvement. In our case series report, we saw an average of improvement of 0.12 LogMAR in the first week postoperative visit, 0.24 LogMAR at 3<sup>rd</sup> month, and 0.4 LogMAR at 6<sup>th</sup> month postoperative. However, one of the five cases did not show improvement of BCVA despite the closure and structural improvement of the MH, this might be due to the large defect of MH basal dm and chronicity, compared to the other four cases in which this allows us to contemplate the need of a retinal autologous transplant<sup>26</sup> (>1000 µm) for these kind of cases; however, all of them resulted in structural improvement and none needed a repeated surgery or suffered any complications during or after the surgery.

## **Conclusion**

ILM inverted flap technique with fluid-air exchange with 24 hours prone positioning seems to be a safe and effective surgery in large MH cases, improving anatomic and visual outcomes for our patients, without the need of performing a second surgery because of reopening. One potential limitation of this study is the short time of follow up and the relatively small sample size, further studies are needed to continue comparing the results.

## **References**

1. McCannel CA, Ensminger JL, Diehl NN, Hodge DN. Population-based incidence of macular holes. *Ophthalmology*. 2009;116(7):1366–9.
2. Shroff D, Gupta P, Atri N, Gupta C, Shroff C. Inverted internal limiting membrane (ILM) flap technique for macular hole closure: patient selection and special considerations. *Clin Ophthalmol*. 2019;13:671–8.
3. Michalewska Z, Michalewski J, Adelman RA, Nawrocki J. Inverted internal limiting membrane flap technique for large macular holes. *Ophthalmology*. 2010;117(10):2018–25.

4. Spiteri Cornish K, Lois N, Scott N, Burr J, Cook J, Boachie C, et al. Vitrectomy with internal limiting membrane (ILM) peeling versus vitrectomy with no peeling for idiopathic full-thickness macular hole (FTMH). *Cochrane Database Syst Rev*. 2013;(6):CD009306.
5. Hillenkamp J, Kraus J, Framme C, Jackson TL, Roider J, Gabel V-P, et al. Retreatment of full-thickness macular hole: predictive value of optical coherence tomography. *Br J Ophthalmol*. 2007;91(11):1445–9.
6. Ittarat M, Somkijrungrroj T, Chansangpetch S, Pongsachareonnont P. Literature review of surgical treatment in idiopathic full-thickness macular hole. *Clin Ophthalmol*. 2020;14:2171–83.
7. Michalewska Z, Nawrocki J. Repeat surgery in failed primary vitrectomy for macular holes operated with the inverted ILM flap technique. *Ophthalmic Surg Lasers Imaging Retina*. 2018;49(8):611–8.
8. Smiddy WE, Sjaarda RN, Glaser BM, Flynn HW Jr, Thompson JT, Hanham A, et al. Reoperation after failed macular hole surgery. *Retina*. 1996;16(1):13–8.
9. Thompson JT, Sjaarda RN. Surgical treatment of macular holes with multiple recurrences. *Ophthalmology*. 2000;107(6):1073–7.
10. Vélez-Montoya R, Ramírez-Estudillo JA, Sjöholm-Gómez de Liaño C, Bejar-Cornejo F, Sanchez-Ramos J, Guerrero-Naranjo JL, et al. Inverted ILM flap, free ILM flap and conventional ILM peeling for large macular holes. *Int J Retina Vitreous [Internet]*. 2018;4(1).
11. Majumdar S, Tripathy K. Macular Hole. In: *StatPearls*. Treasure Island (FL): StatPearls Publishing; 2021.
12. Michalewska Z, Michalewski J, Dulczewska-Cichecka K, Adelman RA, Nawrocki J. Temporal inverted internal limiting membrane flap technique versus classic inverted internal limiting membrane flap technique: A comparative study: A comparative study. *Retina*. 2015;35(9):1844–50.
13. Caicedo A, Espinosa-Heidmann DG, Piña Y, Hernandez EP, Cousins SW. Blood-derived macrophages infiltrate the retina and activate Muller glial cells under experimental choroidal neovascularization. *Exp Eye Res*. 2005;81(1):38–47.
14. Ito Y, Terasaki H, Takahashi A, Yamakoshi T, Kondo M, Nakamura M. Dissociated optic nerve fiber layer appearance after internal limiting membrane peeling for idiopathic macular holes. *Ophthalmology*. 2005;112(8):1415–20.

15. Chandra A, Charteris DG, Yorston D. Posturing after macular hole surgery: a review. *Ophthalmologica*. 2011;226 Suppl 1(s1):3–9.
16. Jumper JM, Gallemore RP, McCuen BW 2nd, Toth CA. Features of macular hole closure in the early postoperative period using optical coherence tomography. *Retina*. 2000;20(3):232–7.
17. Satchi K, Patel CK. Posterior chamber compartments demonstrated by optical coherence tomography, in silicone-filled eyes, following macular hole surgery. *Clin Experiment Ophthalmol*. 2005;33(6):619–22.
18. Isomae T, Sato Y, Shimada H. Shortening the duration of prone positioning after macular hole surgery--comparison between one week and one day. *Nihon Ganka Gakkai Zasshi*. 2001;105(3):167–70.
19. Sano M, Inoue M, Itoh Y, Kita Y, Hirota K, Koto T, et al. Duration of prone positioning after macular hole surgery determined by swept-source optical coherence tomography. *Retina*. 2017;37(8):1483–91.
20. Tornambe PE, Poliner LS, Grote K. Macular hole surgery without face-down positioning. A pilot study. *Retina*. 1997;17(3):179–85.
21. Takai Y, Tanito M, Sugihara K, Kodama T, Ohira A. Temporal inverted internal limiting membrane flap technique for a macular hole patient unable to maintain postoperative prone positioning. *Retin Cases Brief Rep*. 2016 Autumn;10(4):323–6.
22. Xia S, Zhao X-Y, Wang E-Q, Chen Y-X. Comparison of face-down posturing with nonsupine posturing after macular hole surgery: a meta-analysis. *BMC Ophthalmol*. 2019;19(1):34.
23. Ghassemi F, Khojasteh H, Khodabande A, Dalvin LA, Mazloumi M, Riazi-Esfahani H, et al. Comparison of three different techniques of inverted internal limiting membrane flap in treatment of large idiopathic full-thickness macular hole. *Clin Ophthalmol*. 2019;13:2599–606.
24. Casini G, Mura M, Figus M, Loiudice P, Peiretti E, De Cillà S, et al. Inverted internal limiting membrane flap technique for macular hole surgery without extra manipulation of the flap. *Retina*. 2017;37(11):2138–44.
25. Andrew N, Chan WO, Tan M, Ebnetter A, Gilhotra JS. Modification of the inverted internal limiting membrane flap technique for the treatment of chronic and large macular holes. *Retina*. 2016;36(4):834–7.

26. Ma F-Y, Xi R-J, Chen P-F, Hao Y-H. Free autologous internal limiting membrane transplantation in the treatment of large macular hole. *Int J Ophthalmol.* 2019;12(5):848–51.
27. Mahalingam P, Sambhav K. Surgical outcomes of inverted internal limiting membrane flap technique for large macular hole. *Indian J Ophthalmol.* 2013;61(10):601–3.
28. Silva N, Ferreira A, Nawrocka Vel Michalewska ZA, Meireles A. Inverted internal limiting membrane flap technique: Is it the best option for macular holes? *Clin Ophthalmol.* 2021;15:3295–303.